Murphy's Sign of Cholecystitis

Series Editor and Contributing Author: *Frank L. Urbano, MD*
Contributing Author: *MaryBeth Carroll, RN, BSN*

Cholecystitis is a common condition that results from inflammatory, infectious, metabolic, neoplastic, and congenital disorders. The greatest incidence of acute cholecystitis occurs in adults 30 to 80 years of age. There is a 2 times greater incidence of gallstones in women than in men.[1]

Cholecystitis is characterized by a recurring mild-to-moderate, right upper quadrant and epigastric abdominal pain. Pain often radiates to the right posterior scapula and back. Nausea, vomiting, low-grade fever, and leukocytosis are often present. Symptoms are commonly associated with consumption of high-fat meals 1 or more hours prior to the onset of pain.[1-4]

Murphy's sign may be a useful tool in establishing the diagnosis of cholecystitis. Confirmation of the diagnosis depends on a combination of physical findings and laboratory and imaging studies. A corollary, the sonographic Murphy's sign, may be useful as well.[1-5]

SIGNS OF CHOLECYSTITIS

MURPHY'S SIGN

Elicitation: Palpate the right subcostal area while the patient inspires deeply

Positive response: The patient feels pain upon this maneuver and may have an associated inspiratory arrest

SONOGRAPHIC MURPHY'S SIGN

Elicitation: Palpate the right subcostal area using an ultrasound transducer while the patient inspires deeply

Positive response: The patient feels pain upon this maneuver, and the ultrasound transducer can confirm that the gallbladder is being pushed when the patient experiences inspiratory arrest

HISTORIC PERSPECTIVE

John B. Murphy (1857–1916) was a prominent Chicago surgeon from the 1880s through the early 1900s. He was well known for his thoracoplasty procedures,[6,7] and also made valuable contributions to vascular, urologic, neurologic, and orthopaedic surgery.[8] In 1903, Murphy described a hypersensitivity elicited by deep palpation in the subcostal area when a patient with presumed gallbladder disease takes a deep breath. This hypersensitivity was later termed *Murphy's sign*, and is 1 of at least 5 physical signs attributed to him.[9]

ELICITATION

While the examiner palpates the right subcostal region (**Figure 1**), the patient is instructed to take a deep breath, causing the gallbladder to descend toward the examiner's hand. When this maneuver elicits a painful response from the patient, it is considered a positive Murphy's sign.[1-4]

Patients with cholecystitis often experience distress with this maneuver and may have a sudden cessation of inspiration when the inflamed gallbladder reaches the examining fingers. This is termed *inspiratory arrest* and has been described as a "shutting off" of the inspiration.[9]

The *sonographic Murphy's sign* is similar to the Murphy's sign elicited during an abdominal examination. In the sonographic Murphy's sign, however, a positive response is produced by palpation with an ultrasound transducer. This maneuver is considered more accurate than palpation with the hand because the ultrasound transducer can confirm that the gallbladder is being pushed when the patient experiences the pain and inspiratory arrest.[5,10] However, no studies have directly compared the accuracy of the classic versus the sonographic Murphy's sign.

Ms. Carroll is a nurse with Partners in Primary Care, Medford, NJ, and a candidate for a Masters degree in Science, Primary Care of the Adult and Aged, Nurse Practitioner Program, at Rutgers, the State University of New Jersey, Camden. Dr. Urbano is in general internal medicine, Partners in Primary Care, Medford, NJ.

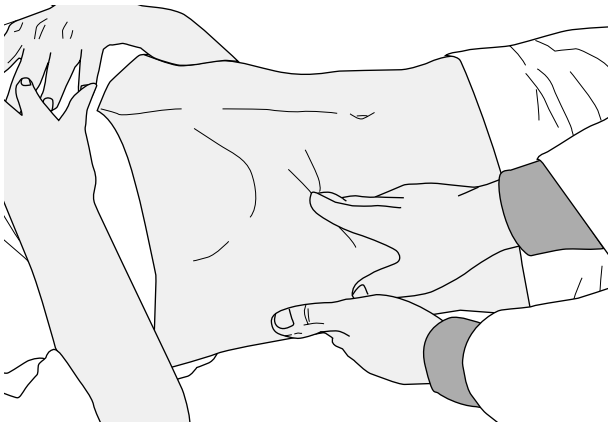

Figure 1. Elicitation of the Murphy's sign of cholecystitis.

PATHOPHYSIOLOGY

In cholecystitis, the gallbladder becomes inflamed secondary to blockage of the cystic duct, usually by a gallstone.[1,3,4] Subsequently, this inflammation causes the release of prostaglandins, which cause more inflammation of the gallbladder.[1] Patients with acute cholecystitis experience discomfort with the Murphy's sign maneuver because the inflamed gallbladder descends toward the examiner's fingers, which irritates the peritoneum, thereby causing pain.[9] Abdominal examination often elicits voluntary and involuntary guarding in these patients.

CLINICAL UTILITY OF MURPHY'S SIGN

The diagnosis of cholecystitis is achieved through a combination of history, physical examination, and laboratory and radiologic studies. Characteristic findings include pain on deep inspiration, abdominal distention and hypoactive bowel sounds, and leukocytosis with or without elevations in serum bilirubin and aminotransferase levels. Radiologic studies that may be of use include plain radiographs, oral cholecystogram, ultrasound, and radioisotope scans.[3,4,11]

Elicitation of Murphy's sign is a useful diagnostic tool when evaluating for cholecystitis, but relatively few studies have examined its clinical accuracy. In a study that compared various clinical measures of cholecystitis to hepatobiliary scanning, the estimated sensitivity of Murphy's sign was 97.2%, and the specificity was 48.3%.[12] The positive predictive value in this study was 70%, and the negative predictive value was 93.3%. This led the authors to conclude that a positive Murphy's sign was highly predictive of a positive hepatobiliary scan (and in turn, of cholecystitis), but that if Murphy's sign was negative and no further workup was pursued, 3% of cases of acute cholecystitis would be missed.

Clinical Utility of the Sonographic Murphy's Sign

The utility of the sonographic Murphy's sign in the diagnosis of cholecystitis has been studied much more extensively. Estimates of the sensitivity of this test range from 63% to 86%, and specificity ranges from 35% to 94%.[13,14] Overall, the accuracy of the sonographic Murphy's sign has been estimated to be 87.2%.[13]

The sonographic Murphy's sign has been compared to other modalities. In a study of patients with proven gangrenous cholecystitis, the sonographic Murphy's sign was not as accurate as other ultrasound characteristics (eg, dilated gallbladder, gallbladder wall thickening, pericholecystic fluid).[15] Another study showed color doppler imaging (CDI) of the gallbladder to be more sensitive than a positive sonographic Murphy's sign.[16] A possible reason for this observation is that CDI can show hyperemic changes in the walls of the inflamed gallbladder.

SUMMARY

Murphy's sign may be a useful diagnostic tool when cholecystitis is suspected. Clinicians cannot depend solely on Murphy's sign or sonographic Murphy's sign for diagnosis, but must also consider laboratory and imaging studies. Each patient's case should be evaluated individually to determine the appropriate diagnosis and treatment plan. **HP**

ACKNOWLEDGMENT

The authors would like to acknowledge Steven Scuderi, MD, for his help with this article.

REFERENCES

1. Shiffer SW, Buttaro TM: Cholelithiasis and cholecystitis. In *Primary Care: A Collaborative Practice.* Buttaro TM, Trybulski J, Bailey PP, Cook JS, eds. St. Louis: Mosby, 1999:486–491.
2. Kalliafas S, Ziegler DW, Flancbaum L, Choban PS: Acute acalculous cholecystitis: incidence, risk factors, diagnosis, and outcome. *Am Surg* 1998;64:471–475.
3. Uphold CR, Graham MV: *Clinical Guidelines in Adult Health,* 2nd ed. Gainesville, FL: Barmarrae Books, 1999: 418–419.
4. Malet PF, Soloway RD: Diseases of the gallbladder and bile ducts. In *Cecil Textbook of Medicine,* 19th ed. Wyngaarden JB, Smith LH Jr, Bennett JC, eds. Philadelphia: Saunders, 1992:804–812.
5. Bree RL: Further observations on the usefulness of the sonographic Murphy sign in the evaluation of suspected acute cholecystitis. *J Clin Ultrasound* 1995:23;169–172.

(continued on page 70)

(from page 52)

6. Milloy F: The contributions of John B. Murphy to thoracic surgery. *Surg Gynecol Obstet* 1990:171;421–432.
7. Dorland WA: *Dorlands Illustrated Medical Dictionary*, 29th ed. Philadelphia, PA: Saunders, 2000:1141.
8. Firkin BG, Whitworth JA: *Dictionary of Medical Eponyms*, 2nd ed. New York: Parthenon Publishing, 1996:277.
9. Aldea PA, Meehan JP, Sternbach G: The acute abdomen and Murphy's signs. *J Emerg Med* 1986;4:57–63.
10. Colletti PM, Cirimelli K, Siegel ME, et al: The scintigraphic Murphy sign. *Eur J Nucl Med* 1988;14:495–497.
11. Greenberger N, Isselbacher KJ: Liver and biliary tract disorders. In *Harrison's Principles of Internal Medicine*. Isselbacher KJ, et al, eds. New York: McGraw Hill, Health Professionals Division, 1994:1504.
12. Singer AJ, McCracken G, Henry MC, et al: Correlation among clinical, laboratory, and hepatobiliary scanning finding in patients with suspected acute cholecystitis. *Ann of Emerg Med* 1996;28:267–272.
13. Ralls PW, Halls J, Lapin SA, et al: Prospective evaluation of the sonographic Murphy sign in suspected acute cholecystitis. *J Clin Ultrasound* 1982;10:113–115.
14. Bree RL: Further observations on the usefulness of the sonographic Murphy sign in the evaluation of suspected acute cholecystitis. *J Clin Ultrasound* 1995;23:169–172.
15. Simeone JF, Brink JA, Mueller PR, et al: The sonographic diagnosis of acute gangrenous cholecystitis: importance of the Murphy's sign. *AJR Am J Roentgenol* 1989;152:289–290.
16. Schiller VL, Turner PR, Sarti DA: Color doppler imaging of the gallbladder wall in acute cholecystitis: sonographic-pathologic correlation. *Abdom Imaging* 1996;21:233–237.

Copyright 2000 by Turner White Communications Inc., Wayne, PA. All rights reserved.